

ORIGINAL ARTICLE

*Assessing Incidence and Variations of Accessory Renal Arteries Pertaining to Origin, Branching and Patterns of Segmentation: A Cross Sectional Study*Shrinivas S. Londhe¹, Balu G. Londhe¹ and Medha G Puranik¹¹Department of Anatomy¹Bharati Vidyapeeth Deemed to be University Medical College, Pune-411043, Maharashtra, India**Abstract:**

Background: Accessory renal arteries (ARAs) typically derive from the multiple structures namely abdominal aorta, common iliac, coeliac trunk, and superior mesenteric and inferior mesenteric arteries. In any surgical procedure, unfamiliarity of the presence of ARAs can cause serious outcome. The present study was done to assess number, origin and branching pattern of accessory renal arteries. *Material and Methods:* A Cross-sectional study was executed at Anatomy Department of one of the private medical colleges in Pune between January 2015 to April 2017 in which total 40 formalin fixed human cadaveric kidneys were dissected and inspected for morphological features. Mean length, thickness and breadth of kidneys were noted. Anterior and posterior branching patterns, various segmental structures and associated variations of ARAs were noted. The data was entered into Microsoft Office Excel Sheet and analysed with SPSS Version 25 Software. *Results:* In the current study, total no of ARAs received were 12(30%) from 40 kidneys. Out of 12, six (50 %) were from right side and remaining 6 (50 %) from left side. Pre-hilar multiple branching pattern of ARA was detected only in 7 (17.5%) specimens. The study could not reveal any statistically significant differences in the morphological features of kidneys with renal artery as well as ARA ($p>0.05$). *Conclusions:* There is need to strengthen knowledge about variations of the ARAs due to growing number of renal transplantations, vascular reconstructions, urological and radiological techniques in recent period. Also, it is essential to conduct further studies to know potential implications of the co-existence of ARAs and other atypical vascularization which may be major risk factor during surgical procedures.

Keywords: Anatomical; Abdominal; Accessory Renal Arteries; Aorta.

Introduction:

Renal vascularization variants immensely differ amongst persons because of complex embryogenesis of the kidneys. Besides, each variant can have implications for clinical as well as surgical interventions. ^[1]Accessory renal arteries (ARAs) are a common variant of the renal arteries. They occur around 25% of the population and may be bilateral in 10% of cases. ^[2]Precise identification of ARAs is essential for various operative procedures like renal transplantation, renal artery embolization, nephrectomy etc. to prevent further complications. ^[2]The conclusive evidence also shows that ARAs can lead to hypertension due to poor renal perfusion because of its narrow caliber which enhances its resistance. ^[3-5]Accessory renal arteries and their position are common. They usually derive from the multiple structures namely abdominal aorta, common iliac, coeliac trunk, and superior mesenteric and inferior mesenteric arteries. ^[3-5] Furthermore variations in number - double, triple and quadruple of renal arteries have also been documented. ^[6-8] Accessory renal vessels may be accompanied with multiple vascular variations comprising testicular, suprarenal, and inferior phrenic vessels. ^[9-11] The frequency of occurrence of ARAs differs in a comprehensive range of studies. It was detected in almost 30% of normal subjects as highlighted in few studies. ^[2, 12] The variations in ARAs have been strongly associated with ethnicity. ² Hence, knowledge of anatomic variants in every population is highly valuable. Its incidence in Malaysians, Africans, and Caucasians was documented as 4%, 37% and 35 % respectively. ^[13-15] Satyapal et al. ^[16] reported that the prevalence of ARAs is diverse among populations and is interrelated to their race. However, there is notable discrepancy in incidence of ARAs among Indian population. It reiterates the necessity to explore more knowledge about variations of ARAs among Indians. Similar studies on Indian population are lacking. It is imperative to note that accessory renal arteries (ARA) are end arteries; therefore if they are damaged, the part of

kidney supplied by it is likely to become ischemic. ARAs are regarded as persistent embryonic lateral splanchnic arteries. Accessory vessels to the inferior pole cross anterior to the ureter and may by obstructing the ureter cause hydronephrosis.^[3-5]In contemporary period, several conservative approaches of surgery of the renal artery are evolving. Therefore, a precise acquaintance of renal vasculature has become a requisite. Familiarity of the existence of ARAs is essential; otherwise, they can get inadvertently impaired during renal surgeries. Besides, their existence should be considered while assessing a donor's kidney for renal transplantation. The study can also be beneficial to medical professionals in conducting invasive methods, vascular surgeries, uro-radiological procedures as well as during managing trauma cases. Considering all these aspects, this study was undertaken to assess variations in morphology of Accessory renal arteries in terms of its number, origin and branching pattern. An attempt was also made to evaluate the comparison of Morphological features of Kidneys with and without ARA. The emerged results of the study may be beneficial especially in Indian settings to prevent the possibility of bleeding due to accidental trauma to ARA and subsequent postoperative morbidity and mortality.

Material and Methods:

A Cross sectional study design was implemented at Department of Anatomy of one of the private medical colleges in Pune, Maharashtra between January 2015 to April 2017. An Ethical approval was attained from Institutional Ethics Committee. All total 40 human cadaveric structurally intact kidneys which were formalin fixed were taken, dissected and examined. Of 40(20 pairs) kidneys from same cadaver, twenty (50%) belonged to right side and 50% were from left side. The study samples were taken through convenience sampling method. The study samples were available in the department over the period of two years during dissection batches of students. All 40 anatomically intact formalin fixed kidneys from available human cadavers were included in the study. The kidneys with anatomical damage were not considered for the study. The renal and accessory renal arteries were dissected through the substance of kidney and the divisions of renal artery as well as ARAs were noted and accordingly the segments were named. During dissection, in situ ARAs were noted. Mean length, thickness and breadth of kidneys were measured. Anterior and posterior branching patterns, various segmental structures and associated variations of ARAs were also documented. In the study, accessory renal artery (ARA) was named as the artery other than renal

artery supplying the kidney which maybe a branch of renal artery itself or arising from aorta or its other branches and mayor may not enter through hilum. The data was entered into Microsoft Office Excel Sheet and analysed using SPSS Version 25 Software.

Results:

In the present study, the total no of accessory renal arteries (ARA) detected were 12(30%) from 40 kidneys. Out of 12, six (50%) were from right side and remaining 6 (50%) from left side. The detailed segments and branching of ARAs of right kidney are described [Table 1]. The segments were decided and labeled according to Gray’s Anatomy- Textbook of Anatomy.

Table 1: Segmental Structure of Accessory Renal Artery of Right Kidney

Ki dyne	Branching pattern (Anterior branches)					Branching Pattern (Posterior branches)					ARA-segments	
	Apical	Superior	Middle	Inferior	Basal	Apical	Superior	Middle	Inferior	Basal		Total segments
R3	1	0	1	0	0	0	1	1	0	0	4	1-ant-inferior and basal
R9	1	0	1	0	1	1	0	0	0	1	5	1-post-middle, lower,& apical
R11	0	1	1	0	0	1	1	0	1	0	5	1ant inferior
R13	1	0	1	0	0	1	0	1	1	0	5	1-ant-basal and inferior
R16	1	1	1	1	0	1	1	0	0	0	6	1-post-Middle and lower
R18	0	1	1	0	0	1	0	1	1	0	5	1-apical Both sides

R1, R2, R4-R8, R10, R12, R14, R15, R17, R19-R23 = Related to renal artery.

Both kidneys showed presence of accessory renal arteries [Figure 1]. In the present study, out of total 12 ARAs, 11 (91.66%) were found to supply the inferior segment or lower pole but there was no inferior polar

artery found in any specimen. One (8.33%) Accessory renal artery was seen to enter the upper pole of right kidney as upper polar artery. All 12 (100%) accessory renal arteries were direct branches of abdominal aorta. In the present study, pre-hilar multiple branching pattern of ARA was observed only in 17.5 of total specimens and 35% of specimens with ARAs. All the kidneys receiving accessory arteries were single accessory renal arteries as double accessory arteries were not found in the present study.

Table 2: Segmental Structure of Accessory Renal Artery of Left Kidney

No. of kidney	Length (cm)	Breadth (cm)	Thickness (cm)	Pre-hilar branches-more than 1 branch is considered as multiple pre-hilar branching.	No. of Segments
L 1	8.2	3.4	3	5	4
L 2	8.5	3.9	3.5	3	4
L 3	7.5	3.9	3.2	0	7
L 4	7.9	4.1	3.5	4	8
L5 ARA	8.1	3.9	3.8	2	4
L 6	11	2.5	3	3	8
L 7	10.5	3.5	3.8	0	5
L 8	10.2	3.6	3.4	2	8
L9 ARA	8.2	4.1	3.3	1	4
L10 ARA	9	4.5	3.8	5	7
L11 ARA	7.7	4.7	3.9	3	5
L 12	7.8	4.3	3	0	7
L 13	8.3	4.3	3.8	2	8
L 14	11.2	4.1	4.6	3	7
L 15	10.3	4.6	4.5	3	8
L16 ARA	8.3	3.6	3.1	0	6
L17 ARA	9.4	4.7	4.2	5	6

L – 1 to 17 Serial number of Left kidney, ARA – Accessory Renal Artery.

The various measurements of kidney with relation to renal artery and accessory renal artery including mean length, thickness, and pre-hilar branches were noted [Table 3].

Table 3: Comparison of Morphological features of Kidneys with and without ARA

Parameter	Kidneys without ARA (n=28)		Kidneys with ARA (n=12)		P value
	Mean	SD	Mean	SD	
Length (cm)	8.76	1.13	8.73	0.82	0.948
Breadth (cm)	3.88	0.67	4.27	0.54	0.081
Thickness (cm)	3.43	0.57	3.49	0.44	0.736
No. of pre-hilar branches	2.15	1.35	2.08	1.73	0.900
No. of Segments	6.00	1.56	5.17	0.94	0.095

RA= Renal artery, ARA = Accessory renal artery, p<0.05 = statistically significant, SD = Standard deviation.

The study could not reveal any statistically significant differences in the morphological features of kidneys with renal artery as well as ARA (p>0.05). The study reported normal and early branching pattern of renal artery and accessory renal artery [Table 4]. Out of 12 ARAs, pre-hilar multiple branching pattern of ARA was detected in 7 (58.3%) specimens [Table 4]. The difference was statistically not significant (p>0.05).

Table 4: Pre-Hilar Branching Pattern of Accessory Renal Arteries

	Normal	Early branching	Total	P value
RA	06 (21.4%)	22(78.6%)	28(70%)	P>0.05
ARA	05 (41.7%)	07 (58.3%)	12(30%)	
Total	11(27.5%)	29(72.5%)	40(100%)	

RA= Renal artery, ARA = Accessory renal artery, p<0.05 = statistically significant

Figure 1: Left accessory renal artery

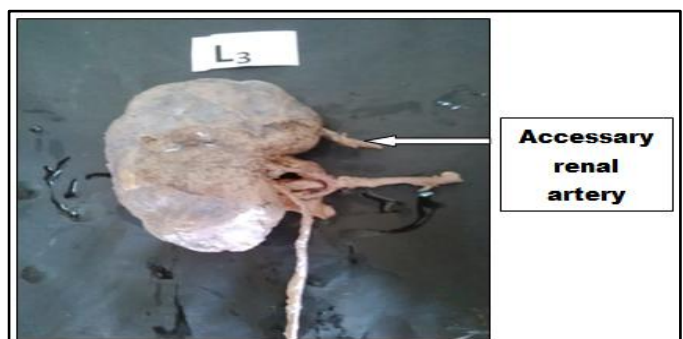

Figure 2: Left accessory renal artery

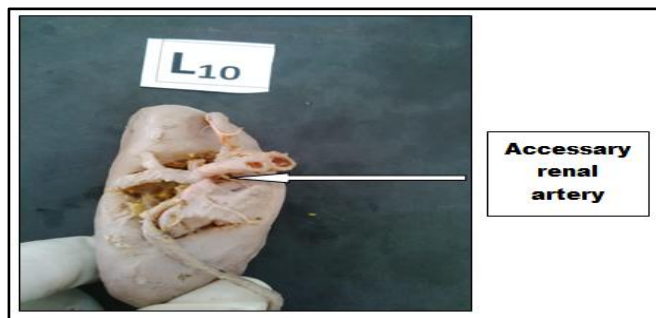

Figure 3: Left accessory renal artery




Figure 4: Left accessory renal artery




Figure 5: Right accessory renal artery

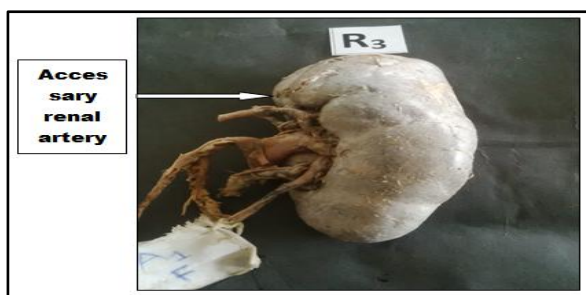

Figure 6: Left accessory renal artery

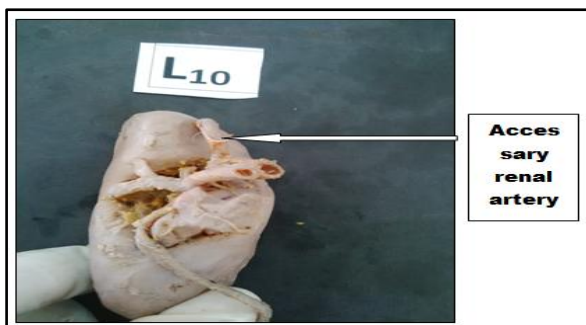



Figure 7: Left accessory renal artery



Discussion:

Due to complex nature of renal embryogenesis, atypical variations in renal vasculature are not uncommon. Accessory renal arteries are additional or supernumerary arteries which either join the central artery near hilum level or pierce the parenchyma distinctly. Extrahilar patterns of ARAs are classically seen as functional end-arteries that are tissue-sustaining vessels lacking anastomoses.^{[17],[18]} In the existing study, the percentage of accessory renal arteries (ARA) was 30% from bilateral kidneys. An anatomical study carried out by Jamkar et al.^[19] found 24.99% as incidence of ARAs. Decker and Du Plessis^[20] mentioned that, there was an accessory renal artery among 15% and 20% of cases on the right and left side respectively. Comparatively, very low percentage (4%) of ARAs was revealed in the study implemented by Hlaing KP et al.^[21] Satyapal et al^[16] conducted a study on 130 organ donors for renal transplantation and 74 corps among African inhabitants and stated that mean prevalence of ARAs was 27.7%. The documented prevalence rate for right kidney was 18.6% and for left kidney was 27.6%. In a different research done by Meyers et al^[22] they revealed that the prevalence of ARAs was 29.3% among Americans. Additionally, Singh et al^[23] reported a prevalence of 30-35% for ARAs among individuals in Singapore. These findings were nearly similar to outcomes of the current study. Accessory renal arteries are common and are predominantly derived from the abdominal aorta.^[1-8] This corroborated with the finding of present study where all ARAs were obtained from abdominal aorta. However, several studies reported diverse inferences. Pestemalci et al.^[24] and Asala et al.^[25] mentioned ARAs originated from common iliac artery. Origin of ARAs from superior and inferior mesenteric has been documented by the study carried out by Lacout et al.^[26] and Gesase AP.^[27] As per the number of accessory arteries as double, triple and quadruple which have been reported in several studies.^[28-30] Similarly, Levine ND et al.^[31] and Shimada K et al.^[32] reported double ARAs whereas Loukas et al.^[33]

observed triplet pattern of accessory renal artery in their study. Contrastingly, the current study found only single ARA which was direct branch of abdominal aorta. In the current study, only one ARA was upper artery. Inferior polar artery was not found though out of total 12 accessory renal arteries. Accessory renal arteries may exist with other vascular variations. Kayalvizhi I et al.^[34] and Bergman RA et al.^[35] found co-existence of testicular arteries along with ARAs. Suprarenal vessels were detected with ARAs in the study performed by Nayak BS.^[28] However, Topaz O et al.^[36] and Bakheit MA et al.^[37] observed inferior phrenic vessels in conjunction with accessory renal arteries in their study. It is imperative to note that, presence of ARAs and the co-existence of other variants of vascularization needs prompt identification as overlooking it during pre-operative measures of patients for surgical procedures can cause lethal complications.^[18-20] Nevertheless, in the current study, there was no evidence of co-existence of any other vascular variant other than ARAs. In the existing study, out of the 12 cases of ARAs, both sides (right and left) had equal ARAs. However, a greater prevalence of ARAs on left side was stated by many authors.^[38, 39] Budhiraja et al.^[40] detected a high incidence (54.7%) of ARAs more on the right side. The research suggests that around 30% of normal individuals may have Aras whereas the incidence may range between 11% to 61%.^[41, 42] The literature shows that the frequency of occurrence of ARAs differs widely with ethnicity.^[2,13] Hence, knowledge of anatomical variants in each population is crucial. The incidence of multiple renal arteries fluctuates largely with ethnicity, ranging from 4% in Malaysians to 61.5% in Indians.⁴³ The frequency of ARAs was observed to be 39.2% in a North Indians^[2] However, it is more common in African (37%) and Caucasian population (35%).^[2] An occurrence of ARAs among Chinese was reported to be 14.5%.^[2] Few studies reported an incidence of 36.1% and 11.2% among Caribbean and Greek population.^[2] Another study mentioned that about 42% of Turkish population had ARAs.^[2] Inferior polar arteries as ARAs are more common than superior polar arteries due to their development. Similar consistent finding was reported by numerous studies.^[40-42] nevertheless; the

present study's observation did not go parallel to the findings of others. In this study, there was one superior polar ARA amongst 12 ARAs i.e. 8.33% on right side. Inferior polar artery was not observed in the present study. However, in the current study, ARAs commonly supplied the lower pole of the kidney even though they were not inferior polar arteries. Out of total 12 accessory renal arteries, 11(91%) had supplied the inferior segment or lower pole. Renal vascular variations are among the commonest variations revealed also in kidney donors. However, Accessory renal artery is the most common variant renal vasculature.^[44-46] It reiterates the need to understand the variations in ARAs to facilitate renal surgical procedures. In this study, the emerged information regarding variations in ARAs may have positive implications when surgery is indicated, as during renal transplantation, urological as well as radiological techniques, renal trauma, renal hypertension, and hydronephrosis. As the numbers of renal surgical and radiological interventions are being escalated, precise understanding of the anatomy of renal arteries, ARAs and their deviations gain significance to plan appropriate surgical interventions and subsequently to prevent associated complications.

Conclusion:

Abnormal uterine bleeding is one of the common gynecological problem encountered in clinical practice and is defined as abnormal bleeding from the uterus in the large volume, longer duration and irregular in frequency. Endometrium is a mirror of histopathology for the hormone dependent and non-hormone dependent causes of AUB in different age groups and is important in detecting the cause for diagnosis and patient management. Endometrial biopsy can be easily procured in AUB cases by D&C, which is simple, cost effective and appropriate method that provide accurate diagnostic yield. The present study highlights the importance of endometrial biopsy and its interpretation which play pivotal role in the management of AUB.

Sources of supports: Nil

Conflicts of Interest: Nil

References

1. Ali AM, Elseed AR, Alamin AK, Gomaa HM. Accessory renal vessels. *Acta Informatica Medica* 2012; 20:196-197.
2. Gulas E, Wysiadecki G, Szymanski J, Majos A, Stefanczyk L, Topol M. Morphological and clinical aspects of the occurrence of accessory (multiple) renal arteries. *Archives of Medical Science*. 2018; 14:442-453.
3. Moore KL, Persuad TV, Torchia MG. Before we are born: *Essentials of embryology and birth defects*. 9th ed. Philadelphia: Elsevier; 2016.161-188.

4. Urban BA, Ratner LE, Fishman EK. Three-dimensional volume-rendered CT angiography of the renal arteries and veins: normal anatomy, variants, and clinical application. *Radiographics*. 2001; 21:373–386.
5. Hosaka A, Miyata T, Nishiyama A, Miyahara T, Hoshina K, Shigematsu K . Preservation of the accessory renal arteries after endovascular repair of common iliac artery aneurysm using kissing stent grafts. *Journal of Vascular Surgery* 2016; 63:523–526.
6. Majos M, Polgaj M, Szemraj RZ, Arazinska A, Stefanczyk L. The level of origin of renal arteries in horseshoe kidney versus in separated kidneys: CT-based study. *Surgical and Radiologic Anatomy*. 2018; 40:1185–1191.
7. Jyothsna P, Mohandas RK, Somayaji S, Ashwini L. Multiple vascular anomalies involving testicular, suprarenal arteries and lumbar veins. *North American Journal of Medicine and Science*. 2012; 4:154-156.
8. Natsis K, Paraskevas G, Panagouli E. A morphometric study of multiple renal arteries in Greek population and a systemic review. *Romanian Journal of Morphology and Embryology* 2014; 55:1111–1122.
9. Sungura RE. The CT angiography pattern of renal arterial anatomy among Africans and its implication on renal transplantation: a cross sectional descriptive study at Kenyatta National Hospital. *Digital Repository*. 2012; 56:307-311.
10. Malgor RD, Oderich GS, Vrtiska TJ, Kalra M., Duncan AA, Gloviczki P. A case-control study of intentional occlusion of accessory renal arteries during endovascular aortic aneurysm repair. *Journal of Vascular Surgery* 2013; 58:1467–1475.
11. Cilingiroglu M, Marmagkiolis K, Wholey M. Successful recanalization of a left common iliac artery chronic total occlusion adjacent to an ectopic renal artery at the aortoiliac bifurcation. *Archives of Turkish Society of Cardiology*. 2013; 41:347–350.
12. Zhang Q, Ji Y, Tianwei H, Wang J. Ultrasound-guided percutaneous renal biopsy-induced accessory renal artery bleeding in an amyloidosis patient. *Diagnostic Pathology* 2012;7:176-181.
13. Choi SS, Kim SC, Han DJ. Clinical outcome of microsurgical multiple renal artery reconstruction in renal transplantation. *Journal of Korean Society Transplant*. 1997;11:81–94.
14. Khamanarong K, Prachaney P, Utraravichien A, Tong UT, Sriparaya K. Anatomy of renal arterial supply. *Clinical Anatomy* 2004;17:334–336.
15. Muktyaz H, Mahboobul H, Nema U, Khalid H, Nigar H. Bilateral variation of renal artery and its clinical significance in North Indian population. *Innovative Journal of Medical and Health Sciences* 2013; 3:121–123.
16. Satyapal KS, Haffejee AA, Singh B, Ramsaroop L, Robbs JV, Kalideen JM. Additional renal arteries: incidence and morphometry. *Surgical and Radiologic Anatomy* 2001; 23:33–38.
17. Amirzargar MA, Babolhavaeji H, Hosseini SA. The new technique of using the epigastric arteries in renal transplantation with multiple renal arteries. *Saudi Journal of Kidney Diseases and Transplantation* 2013; 24:247–53.
18. Yufa A, Mikael A, Lara G, Nurick H, Andacheh I. Accessory renal arteries involved in atherosclerotic occlusive disease at the aortic bifurcation. *Journal of Vascular Surgery Cases, Innovations and Techniques* 2020; 6:425-429.
19. Jamkar AA, Khan B, Joshi DS. Anatomical study of renal and accessory renal arteries. *Saudi Journal of Kidney Diseases and Transplantation* 2017; 28:292-297.
20. Decker GA, Du Plessis DJ. Lee Mc'Gregor's synopsis of surgical anatomy. 12th ed. India: Bombay KM Varghese; 1986.289-300.
21. Hlaing KP, Das S, Sulaiman IM, Abd LA, Suhaimi FH, Othman F. Accessory renal vessels at the upper and lower pole of the kidney: a cadaveric study with clinical implications. *Bratislavckelekarskelisty* 2010; 111:308-310.
22. Meyers SP, Talagala SL, Totterman S, Azodo MV, Kwok E, Shapiro L et al. Evaluation of the renal arteries in kidney donors: value of three-dimensional phase-contrast MR angiography with maximum-intensity-projection or surface rendering. *American Journal of Roentgenology* 1995; 164:117–121.
23. Singh G, Ng Y, Bay B. Bilateral accessory renal arteries associated with some anomalies of the ovarian arteries: a case study. *Clinical Anatomy* 1998; 11:417–420.
24. Pestemalci T, Mavi A, Yildiz YZ, Yildirim M, Gumusburun E. Bilateral triple renal arteries. *Saudi Journal of Kidney Diseases and Transplantation* 2009;20:468–70.
25. Asala SA, Asumbuko NM, Bidmos MA. An unusual origin of supernumerary renal arteries: case report. *East African Medical Journal* 2001; 78:686–687.
26. Lacout A, Thariat J, Marcy PY. Main right renal artery originating from the superior mesenteric artery. *Clinical Anatomy* 2011; 6:1-10.
27. Gesase AP. Rare origin of supernumerary renal vessels supplying the lower pole off the left kidney. *Annals of Anatomy* 2007; 189:53–58.

28. Nayak BS. Multiple variations of the right renal vessels. *Singapore Medical Journal* 2008;49:153–155.
29. Kara A, Kurtoglu Z, Oguz U, Ozturk AH, Uzmanse D. Two accessory renal arteries with histological properties. *Turkish Journal of Medical Sciences* 2006; 36 :133–138.
30. Madhyastha S, Suresh R, Rao R. Multiple variations of renal vessels and ureter. *Indian Journal of Urology* 2001; 17:164–165.
31. Levine ND. An unusual renal arterial anomaly: common origin of arteries to the lower poles. *British Journal of Radiology* 1970; 43:66–67.
32. Shimada K, Ohashi I, Sakai Y, Kijima T, Yoshida S, Okuno T et al. An unusual renal vascular anomaly: common origin of arteries to the lower poles demonstrated by a computed tomography angiography using 16-slice multidetector computed tomography. *Acta Radiologica* 2006; 47:332–334.
33. Loukas M, Aparicio S, Beck A, Calderon R, Kennedy M. Rare case of right accessory renal artery originating as a common trunk with the inferior mesenteric artery: a case report. *Clinical Anatomy* 2005; 18:530–535.
34. Kayalvizhi I, Monisha B, Usha D. Accessory left testicular artery in association with double renal vessels: a rare anomaly. *Folia Morphologica* 2011; 70(4):309–311.
35. Bergman RA, Cassell MD, Sahinoglu K, Heidger PM. Human doubled renal and testicular arteries. *Annals of Anatomy* 1992; 174:313–315.
36. Topaz O, Topaz A, Polkampally PR, Damiano T, King CA. Origin of a common trunk for the inferior phrenic arteries from the right renal artery: a new anatomic vascular variant with clinical implications. *Cardiovascular Revascularization Medicine* 2010; 11:57–62.
37. Bakheit MA, Motabagani MA. Anomalies of the renal, phrenic and suprarenal arteries: case report. *East African Medical Journal* 2003; 80:497–498.
38. Bordei P, Sapte E, Ilescu D: Double renal arteries originating from the aorta. *Surgical and Radiological Anatomy* 2004, 26:474-449.
39. Vilhova I, Kryvko YY, Maciejewski R: The radioanatomical research of plural renal arteries. *Folia Morphologica* 2001, 60:337-341.
40. Budhiraja V, Rastogi R, Jain V: Anatomical variations of renal artery and its clinical correlations: a cadaveric study from central India. *Journal of Morphological Sciences* 2013, 30:228-233.
41. Gupta A, Gupta R, Singhla R. The accessory renal arteries: a comparative study in vertebrates with its clinical implications. *Journal of Clinical Diagnostics and Research.* 2011, 5:970-973.
42. Aristotle S, Sundarapandian, Felicia C. Anatomical study of variations in the blood supply of kidneys. *Journal of Clinical Diagnostics and Research* 2013;7:1555-1557.
43. Lee HB, Yang J, Maeng YH, Yoon SP. Bilateral multiple renal arteries with an extra-aortic origin and quadruple testicular veins. *Anatomy and Cell Biology* 2019;52 :518-521.
44. Hostiuc, M.C. Rusu, I. Negoii, B. Dorobanțu, M. G rigoriu. Anatomical variants of renal veins: a meta-analysis of prevalence. *Scientific Reports* 2019; 9:1-15.
45. Kachlík D, I. Varga, V. Baca, V. Musil. Variant anatomy and its terminology. *Medicina* 2020;56: 715.
46. Song, W.H., Baik, J., Choi, EK. et al. Quantitative analysis of renal arterial variations affecting the eligibility of catheter-based renal denervation using multi-detector computed tomography angiography. *Scientific Reports* 2020; 19: 1-10.

Address for correspondence:

Dr. Balu Londhe
Associate Professor,
Department of Anatomy,
Bharati Vidyapeeth Deemed to be University Medical
College, Pune-411043, Maharashtra, India
Mobile no: +91 8605324298
Email: bglondhe61@gmail.com

How to cite this article:

Shrinivas S. Londhe, Balu G. Londhe and Medha G Puranik. Assessing Incidence and Variations of Accessory Renal Arteries Pertaining to Origin, Branching and Patterns of Segmentation: A Cross Sectional Study. *Walawalkar International Medical Journal* 2024;11(1):01-07.
<http://www.wimjournal.com>.